

## Primary mucinous adenocarcinoma of the thymus: A case report

Tomoka Hamahiro<sup>a</sup>, Ryo Maeda<sup>a</sup>, Takanori Ayabe<sup>a</sup>, Yuichiro Sato<sup>b</sup>, Masaki Tomita<sup>a,\*</sup>

<sup>a</sup> Department of Thoracic and Breast Surgery, Faculty of Medicine, University of Miyazaki, Kihara 5200, Kiyotake, Miyazaki, 889-1692, Japan

<sup>b</sup> Department of Pathology, Faculty of Medicine, University of Miyazaki, Kihara 5200, Kiyotake, Miyazaki, 889-1692, Japan

### ARTICLE INFO

#### Keywords:

Primary thymic mucinous adenocarcinoma

### ABSTRACT

Primary thymic mucinous adenocarcinoma is extremely rare; to our knowledge, only 16 cases have been reported to date. A 68-year-old man presented to a previous hospital due to massive pericardial effusion. Cytological examination of the pericardial effusion revealed the presence of adenocarcinoma, and computed tomography showed an anterior mediastinal mass lesion invading the pericardium. Because systemic examination failed to detect other lesions, except for liver metastasis, mediastinal lymph node swelling, and pleural dissemination, a thorascopic biopsy of the mediastinal and pleural tumor was performed. The pathological diagnosis was thymic mucinous adenocarcinoma. Although he received chemotherapy, he died due to cancer 6 months after the biopsy.

### 1. Introduction

Thymic carcinoma is extremely rare among thymic epithelial tumors, and a variety of histological types of this carcinoma has led to great challenges to both clinicians and pathologists [1]. The most commonly known primary thymic carcinomas are squamous cell carcinomas or their variants [1]. Primary mucinous adenocarcinoma of the thymus is extremely rare [2–7]. To our knowledge, only 16 cases have been reported to date [2–7]. Here, we report a case of primary thymic mucinous adenocarcinoma.

### 2. Case report

A 68-year-old man presented to a previous hospital with a diagnosis of acute heart failure. He had undergone prior surgical resection of papillary adenocarcinoma of the thyroid at 3 years before the current presentation. An echocardiogram showed a massive pericardial effusion, and pericardiocentesis was performed. After pericardial drainage, his symptoms, including shortness of breath and dyspnea, were significantly improved. Cytological analysis of the pericardial fluid revealed malignant epithelial cells consistent with the diagnosis of adenocarcinoma. Computed tomography (CT) revealed an anterior mediastinal mass lesion invading the pericardium (Fig. 1A). CT also confirmed swelling of the mediastinal lymph nodes, bilateral pleural effusion, and pleural dissemination (Fig. 1B). He was therefore referred to our hospital with

suspicious mediastinal metastasis of primary unknown malignancy. The serum carcinoembryonic antigen level was 69.2 ng/ml. A review of organ systems revealed a liver lesion, suggesting liver metastasis. However, no other suspicious primary lesions were found. For histological confirmation, a video-assisted thorascopic tumor biopsy was performed. In addition to an incisional biopsy of the mediastinal tumor, a biopsy of the lung pleural nodule was also performed.

Microscopic examination of both tumors showed that cuboidal cancer cells with mucin production proliferated in a fused glandular or small-nested pattern. Extracellular mucin pools and signet-ring-like cells were also noted (Fig. 2). These histological features were not similar to those of thyroid papillary adenocarcinoma. Immunohistochemically, cancer cells are positive for cytokeratin (CK) 20 and caudal type homeobox 2 (CDX-2), and negative for CK7, estrogen receptor, CD5, and thyroid transcription factor-1 (TTF-1) (Fig. 3). The final diagnosis was primary thymic mucinous adenocarcinoma.

Because the tumor was unresectable, he received paclitaxel-carboplatin-based chemotherapy. Due to disease progression, carboplatin and pemetrexed were subsequently administered. However, 6 months after surgery, he died due to cancer progression.

### 3. Discussion

Thymic carcinoma is rare and usually occurs as squamous cell carcinoma or their variants [1]. Primary thymic mucinous adenocarcinoma

\* Corresponding author. Department of Thoracic and Breast Surgery, Faculty of Medicine, University of Miyazaki, Kihara 5200, Kiyotake, Miyazaki, 889-1692, Japan.

E-mail address: [mtomita@med.miyazaki-u.ac.jp](mailto:mtomita@med.miyazaki-u.ac.jp) (M. Tomita).

<https://doi.org/10.1016/j.rmcr.2021.101497>

Received 23 June 2021; Received in revised form 26 July 2021; Accepted 10 August 2021

Available online 12 August 2021

2213-0071/© 2021 The Authors.

Published by Elsevier Ltd.

This is an open access article under the CC BY-NC-ND license

(<http://creativecommons.org/licenses/by-nc-nd/4.0/>).

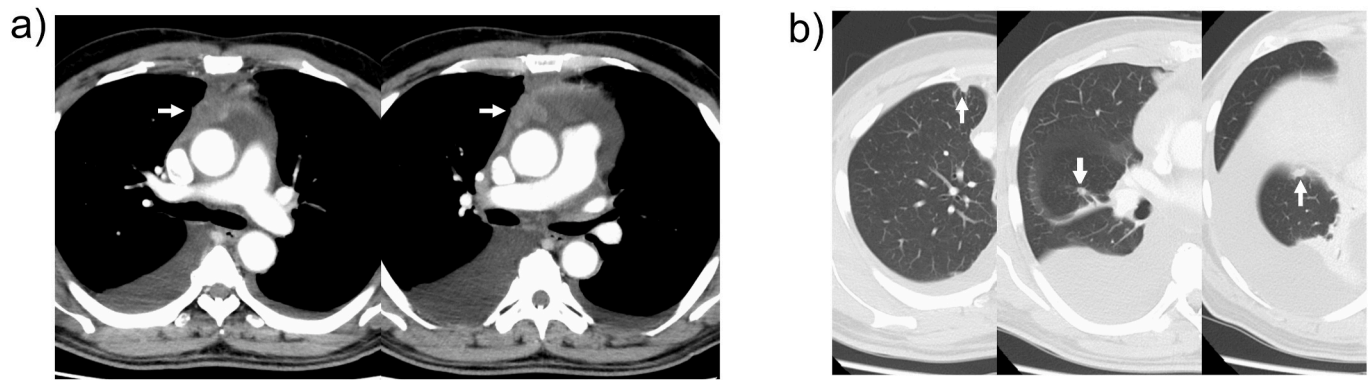


Fig. 1. Computed tomographic findings of the anterior mediastinal tumor (A), and pulmonary lesions (B).

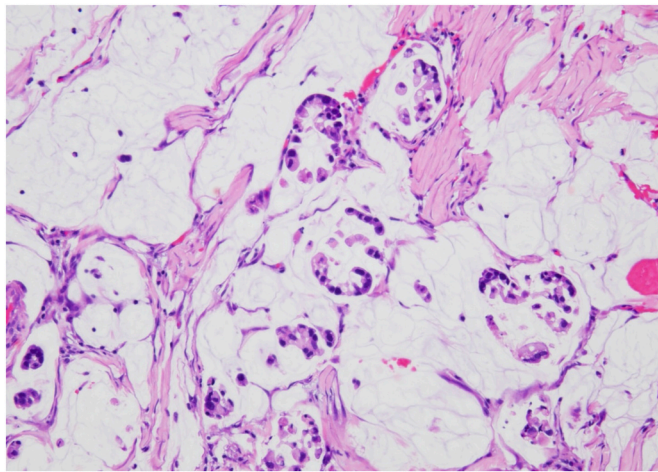


Fig. 2. Microscopic findings of anterior mediastinal tumor (hematoxylin-eosin, original magnification  $\times 100$ ).

itself is extremely rare. To our knowledge, only 16 cases have been reported previously [2–7].

Thymic mucinous adenocarcinoma is rare; hence, it is necessary to exclude metastasis from other primary lesions [2–6]. However, thymic metastases themselves are extremely rare; to our knowledge, there is only one previous report of metastatic thymic mucinous adenocarcinoma from another primary lesion [8]. Furthermore, pericardial effusions are rarely found as the initial manifestation of metastasis [9]. Although lung cancer is the most common cause of pericardial involvement [9], the present tumor was negative for TTF-1, which is an important marker of lung adenocarcinoma. It had also revealed that a combination of TTF-1(–)CK7(–)CK20(+) was hardly associated with primary lung adenocarcinoma [10]. In addition, in the present case, we failed to find suspicious primary lesions, except for liver metastasis and pleural dissemination.

Microscopically, it is difficult to distinguish between primary thymic mucinous adenocarcinoma and metastatic mucinous adenocarcinoma of the gastrointestinal tract, pancreas, breast, lung, and ovary, as they show similar histopathologic features [4,6]. Recently, improved immunohistochemical observations are useful for the differential diagnosis of these tumors. CD5, a lymphocytic biomarker, has been reported to be useful

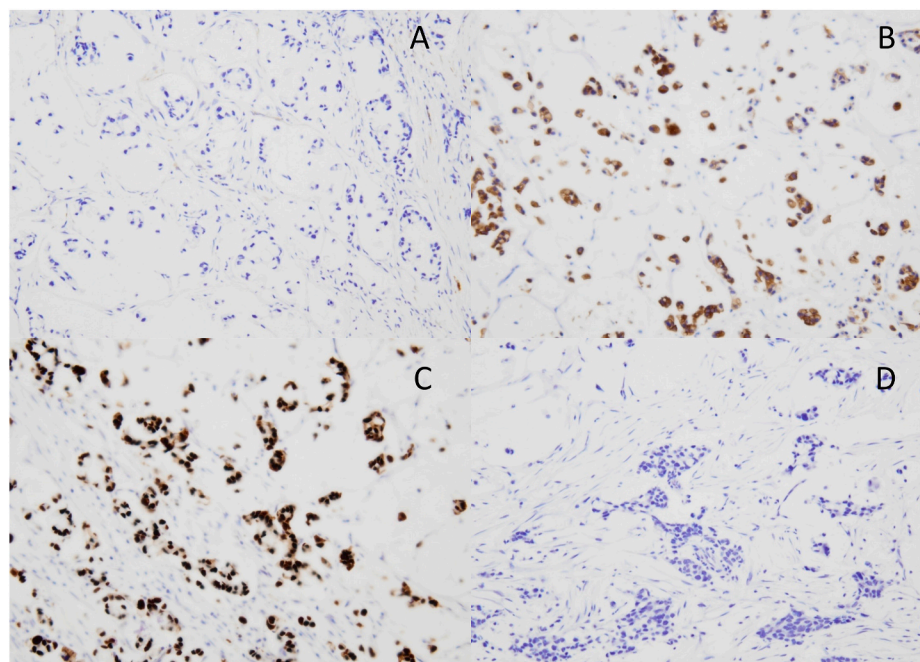


Fig. 3. Immunohistochemical staining. Cancer cells are negative for cytokeratin 7 (A) and thyroid transcription factor-1(D), positive for cytokeratin 20 (B), and caudal-type homeobox 2 (C).

for differentiating thymic from nonthymic carcinoma [11]. On the other hand, Kapur et al. reported that CD5 does not play a decisive role in the diagnosis of primary thymic adenocarcinoma [6]. Abdul-Ghafar et al. also reported that immunostaining is not helpful for differentiating primary thymic mucinous adenocarcinomas from metastatic mucinous ones [4]. Therefore, although the tumor cells of the present case were immunohistochemically negative for CD 5, the patient was diagnosed to have primary mucinous adenocarcinoma of the thymus based on the clinical, pathological, and other immunohistochemical findings. However, there is a possibility that an occult primary lesion might exist.

Kinoshita et al. reviewed 16 cases (8 males and 9 females) of primary thymic mucinous adenocarcinoma [7]. Although adjuvant therapies were administered in 9 cases, whose tumor was incompletely resected or invaded other organs, these therapies did not exhibit satisfactory anti-tumor efficacy, and recurrence of the tumor and early death from cancer were observed [7]. Only 3 patients who received complete resection survived for more than 5 years [7]. It appears that thymic mucinous adenocarcinoma might be more aggressive than other adenocarcinomas. Further clinicopathologic and genetic analysis may lead to a better understanding of this rare disease.

In conclusion, we reported a rare case of primary mucinous adenocarcinoma of the thymus.

#### Declaration of competing interest

The authors declare that they have no competing interests.

#### References

- [1] S. Suster, C.A. Moran, Primary thymic epithelial neoplasms: spectrum of differentiation and histological features, *Semin. Diagn. Pathol.* 16 (1999) 2–17.
- [2] S.H. Ra, M.C. Fishbein, T. Baruch-Oren, P. Shintaku, S.K. Apple, R.B. Cameron, C. K. Lai, Mucinous adenocarcinomas of the thymus: report of 2 cases and review of the literature, *Am. J. Surg. Pathol.* 31 (2007) 1330–1336.
- [3] B. Moser, A.I. Schiefer, S. Janik, A. Marx, H. Prosch, W. Pohl, B. Neudert, A. Scharrer, W. Klepetko, L. Müllauer, Adenocarcinoma of the thymus, enteric type: report of 2 cases, and proposal for a novel subtype of thymic carcinoma, *Am. J. Surg. Pathol.* 39 (2015) 541–548.
- [4] J. Abdul-Ghafar, S.J. Yong, W. Kwon, I.H. Park, S.H. Jung, Primary thymic mucinous adenocarcinoma: a case report, *Korean J Pathol* 46 (2012) 377–381.
- [5] J. Akiba, H. Harada, S. Yokoyama, T. Hashiguchi, A. Kawahara, M. Mitsuoka, S. Takamori, H. Yano, Mucinous cystic tumor with CK20 and CDX2 expression of the thymus: is this a benign counterpart of adenocarcinoma of the thymus, enteric type? *Pathol. Int.* 66 (2016) 29–33.
- [6] P. Kapur, D. Rakheja, M. Bastasch, K.H. Molberg, V.R. Sarode, Primary mucinous adenocarcinoma of the thymus: a case report and review of the literature, *Arch. Pathol. Lab Med.* 130 (2006) 201–204.
- [7] F. Kinoshita, F. Shoji, K. Takada, G. Toyokawa, T. Okamoto, T. Yano, Y. Oda, Y. Maehara, Mucinous adenocarcinoma of the thymus: report of a case, *Gen Thorac Cardiovasc Surg* 66 (2018) 111–115.
- [8] Y. Yamamoto, K. Kodama, Y. Ide, M. Takeda, Thymic and mediastinal lymph node metastasis of colon cancer, *Ann. Thorac. Surg.* 103 (2017) e13–e15.
- [9] C. Chiles, P.K. Woodard, F.R. Gutierrez, K.M. Link, Metastatic involvement of the heart and pericardium: CT and MR imaging, *Radiographics* 21 (2001) 439–449.
- [10] Y.C. Su, Y.C. Hsu, C.Y. Chai, Role of TTF-1, CK20, and CK7 immunohistochemistry for diagnosis of primary and secondary lung adenocarcinoma, *Kaohsiung J. Med. Sci.* 22 (2006) 14–19.
- [11] H. Tateyama, T. Eimoto, T. Tada, H. Hattori, T. Murase, H. Takino, Immunoreactivity of a new CD5 antibody with normal epithelium and malignant tumors including thymic carcinoma, *Am. J. Clin. Pathol.* 111 (1999) 235–240.